

Sussex Research

Disseminated neoplasia in blue mussels, *Mytilus galloprovincialis*, from the Black Sea, Romania

Corina Ciocan, I. Sunila

Publication date

01-01-2005

Licence

This work is made available under the **Copyright not evaluated** licence and should only be used in accordance with that licence. For more information on the specific terms, consult the repository record for this item.

Citation for this work (American Psychological Association 7th edition)

Ciocan, C., & Sunila, I. (2005). *Disseminated neoplasia in blue mussels, Mytilus galloprovincialis, from the Black Sea, Romania* (Version 1). University of Sussex. <https://hdl.handle.net/10779/uos.23310842.v1>

Published in

Marine Pollution Bulletin

Link to external publisher version

<https://doi.org/10.1016/j.marpolbul.2005.04.042>

Copyright and reuse:

This work was downloaded from Sussex Research Open (SRO). This document is made available in line with publisher policy and may differ from the published version. Please cite the published version where possible. Copyright and all moral rights to the version of the paper presented here belong to the individual author(s) and/or other copyright owners unless otherwise stated. For more information on this work, SRO or to report an issue, you can contact the repository administrators at sro@sussex.ac.uk. Discover more of the University's research at <https://sussex.figshare.com/>

Marine Pollution Bulletin 50 (2005), 1335-1339

Disseminated neoplasia in blue mussels, *Mytilus galloprovincialis*, from the Black Sea, Romania

Corina Ciocan^{1,*}, Inke Sunila²

¹National Institute for Marine Research and Development, Grigore Antipa, Mamaia Blv. 300, Constanta 8700, Romania

²State of Connecticut, Department of Agriculture, Bureau of Aquaculture, PO Box 97, Milford, Connecticut 06460, USA

***Email: C.M.Ciocan@sussex.ac.uk**

Fax: 0040 1273 677196

Present address: University of Sussex, Department of Biology and Environmental Sciences, Falmer, Brighton BN1 9RH, UK

KEY WORDS: disseminated neoplasia· hemic neoplasia· leukemia· mussels· *Mytilus galloprovincialis*· Black Sea

Running short title: Ciocan & Sunila: Disseminated neoplasia in Black Sea mussels

ABSTRACT

Disseminated neoplasia, also called leukemia or hemic neoplasia, has been detected in 15 species of marine bivalve mollusks worldwide. The disease is characterized by the presence of single anaplastic cells with enlarged nuclei and sometimes frequent mitosis, in hemolymph vessels and sinuses. The neoplastic cells gradually replace normal hemocytes leading to the increased mortality of animals. The neoplasia reaches epizootic prevalences in blue mussels, *Mytilus trossulus*, in some areas, whereas prevalences in *M. edulis* are generally very low. *M. galloprovincialis* was suggested to be resistant to the disease although very low prevalences were documented from Spain in the Atlantic Ocean and Italy in the Mediterranean Sea. A case of disseminated neoplasia was discovered in *M. galloprovincialis* from among 200 specimens studied from the coast of the Romanian Black Sea. Histological preparation revealed the presence of large anaplastic cells with lobed nuclei. This observation extends the geographic range of marine bivalve mollusks with disseminated neoplasia to include the Black Sea.

INTRODUCTION

Disseminated neoplasia, also called leukemia or hemic neoplasia, has been reported in 15 species of marine or estuarine bivalve mollusks from around the world. Bivalve families affected with the disease include mussels (*Mytilus* spp.), oysters (*Crassostrea* and *Ostrea* spp.), soft shell clams (*Mya* spp.), cockles (*Cerastoderma* spp.) and macoma clams (*Macoma* spp.) (Peters 1988). The condition is characterized by proliferation of anaplastic circulating cells with relatively large nuclei, a high nucleus-to-cytoplasm ratio and frequent presence of mitosis (Elston et al. 1992). The condition has also been called sarcomatoid proliferative disease (Farley 1969), proliferative atypical hemocytic condition (Lowe and Moore 1978), epizootic sarcoma (Farley et al. 1986), sarcomatous neoplasia (Brousseau 1987), transmissible sarcoma (Farley et al. 1991) and systemic neoplasia (Moore et al. 1991). Regardless the nomenclature, this disorder, apparently of hemocytic origin, is distinguishable from another group of bivalve neoplasia, germinomas (reviewed by Peters et al., 1994) even when these cases become invasive and systemic. Branchial carcinoma of the macoma clam (Farley, 1976) presents some difficulties in distinguishing it from disseminated neoplasia.

Disseminated neoplasia in bivalves is progressive and fatal. Anaplastic cells proliferate and replace normal hemocytes in circulation. Elston et al. (1988a) examined the pathogenesis of the disease in individual mussels (*M. trossulus*) from hemolymph preparations over a 4-month period. Fifty percent of the mussels progressed to advanced disease, most of which died, and 20% showed early advancement of the disease, but went

into remission. Proliferating anaplastic cells consist of different cell populations with different ploidy levels, penta- and tetraploid, which are reflected as different morphologies (Elston et al 1990, Moore et al. 1991). Diseased mussels have impaired defense mechanisms after the decline in the number of circulating hemocytes, as demonstrated experimentally by the inability of diseased mussels to clear injected bacteria (Kent et al. 1989).

This disease can be transmitted by inoculating neoplastic cells into healthy mussels (Elston et al. 1988b). Whether the disease in these experiments was transmitted via cell transplantation or an infective agent was unclear. In another bivalve, the soft clam, evidence of retroviral origin was reported in three separate studies (Oprandy et al. 1981, 1983, Medina et al. 1993, House et al. 1998). Interestingly, attempts to transmit mussel neoplasia to other bivalve species such as soft clams (*Mya arenaria*), flat oysters (*Ostrea edulis*) and Olympia oysters (*Ostrea conchophila*), failed. Only mussels developed the disease (Kent et al. 1991).

In some areas disseminated neoplasia reaches epizootic prevalence in selected bivalve species causing serious regional economic damage to the aquaculture industry. Up to 40% prevalence was reported in *Mytilus trossulus* in Puget Sound, Washington, USA (Elston et al. 1988a), 72% in *Cerastoderma edule* in Cork Harbor, Ireland (Twomey & Mulcahy 1988) and 90% in *Mya arenaria* in New Bedford Harbor, Massachusetts, USA (Reinisch et al. 1984). The susceptibility to the disease differs in different species/subspecies of *Mytilus*. A single case of neoplasia in *Mytilus galloprovincialis* was reported among several thousand mussels studied for the Mussel Watch program in

California, USA (Hillman 1990). During a pathology survey of mussels (*Mytilus galloprovincialis*) farmed in Taranto, Manfredonia and Cagnano Varano (Italy) carried out between February and December of 1990, neoplasia was found in two Taranto mussels sampled in March and in four others sampled in July (Tiscar et al. 1990, Zizzo et al. 1991). Another single case of “haemocytic neoplasia” was described in cultured mussels *Mytilus galloprovincialis* from Ria de Arousa, NW of Spain (Figueras et al. 1991a). More than 10 years later, Fuentes et al. (2002) reported disseminated neoplasia in five (out of 135) hatchery-reared mussels from the same location. According to Villalba et al. (1997) disseminated neoplasia should not be considered as a threat to the mussel culture industry in Galicia (NW of Spain) since its prevalence is very low in the region: only five mussels (*Mytilus galloprovincialis*) with a cellular proliferative disorder were reported in 1997. Nevertheless, Elston et al. (1992) suggested that *M. galloprovincialis* is resistant to leukemia.

Here, we report a single case of disseminated neoplasia in *Mytilus galloprovincialis* from Romania, the Black Sea. This is the first report of bivalve neoplasia in the region.

MATERIALS AND METHODS

Mature wild mussels, *Mytilus galloprovincialis*, were collected by divers offshore near Navodari resort, 5 km north of Constanta, Romanian Black Sea coast, during April 1996. 200 individuals of *Mytilus* (50-70mm length) were sampled from a depth of 2.0-2.5m at 15 days intervals (100 individuals/batch).

At the laboratory, mussels were immediately shucked and the tissues preserved in 10% formalin solution for 3-5 days. Specimens were embedded in paraffin and 5µm tissue sections were stained with hematoxylin-eosin-methyl blue (a modified Masson Trichrome). The slides were examined for gonad development to identify the spawning peak, but the individuals were also diagnosed for possible histopathological changes as the sampling site is situated close to a small harbor (Midia Harbor).

RESULTS

One of the histological sections contained mainly gill tissue demonstrating transverse sections of gill filaments. It was characterized by the presence of large, atypical, neoplastic cells (Fig. 1A). Branchial vessels contained no normal hemocytes, but were instead filled with round anaplastic cells (7.36µm, SD=0.80, n=50). Cells had eccentric hyperchromatic indented, lobed or otherwise pleomorphic nuclei (Fig. 1B). Chromatin was granular and no nucleoli were observed. Nucleus to cytoplasm ratios was high and only scant, pale-staining cytoplasm was present. Some cells were binucleated, and a metaphase plate was observed.

DISCUSSION

Mussels (*Mytilus sp.*) have been used as model organisms in histopathology and genetic studies more than any other group of marine invertebrates.

The *Mytilus* spp is a diverse group of bivalves with a broad distribution in the marine environment. Much of the confusion in mussel taxonomy has arisen because of the emphasis placed on shell morphology. Such characteristics are enormously plastic, being subjected to a wide range of environmental factors. Prior to the use of electrophoresis, about nine distinct species of *Mytilus* were recognized: *Mytilus edulis* from northern temperate latitudes, *Mytilus galloprovincialis* from the Mediterranean Sea, *Mytilus trossulus* from the Pacific coast of North America, *Mytilus coruscus* from Japan and China, *Mytilus californianus* from the Pacific coast of North America, *Mytilus chilensis* from Chile, *Mytilus platensis* from Argentina, *Mytilus planulatus* from Australia and *Mytilus desolationis* from the Kerguelen Islands in the southern Indian Ocean (Gosling 1992).

Disseminated neoplasia in blue mussels has been reported from numerous locations worldwide in four different *Mytilus* species (Fig. 2). The reports include *Mytilus galloprovincialis* from the Black Sea (1), Romania (the present study), Mediterranean Sea (2), Italy (Tiscar et al. 1990, Zizzo et al. 1991) and East Atlantic Ocean (3), Galicia, Spain (Figueras et al. 1991, Fuentes et al., 2002, Villalba et al. 1997). Further, there was a single case of disseminated neoplasia in the East Pacific (9), in California, USA in *M. galloprovincialis* (Hillman 1990). Neoplasia has been detected in *M. edulis* in the UK in the Irish Sea (4) and the North Sea (5) (Lowe & Moore 1978, Green & Alderman 1983) and in *M. trossulus* in the Baltic Sea (6), Denmark by Rasmussen (1986) and in Finland by Sunila (1987). In North America, in the West Atlantic, Figueras et al. (1991b) reported a case of disseminated neoplasia in *M. edulis* in Maine, USA, and Hillman et al.

(1992) reported seven cases during six years of the Mussel Watch Program among several thousand mussels studied in Massachusetts, Connecticut and New York (7). Disseminated neoplasia in *M. trossulus* from the Northeast Pacific (8) was reported in several articles in British Columbia, Canada (Cosson-Mannevy et al. 1984, Bower 1989), Oregon (Farley 1969, Mix 1983) and Washington State, USA (Elston et al. 1988a). In South America, in the Southeast Pacific, there is a single report of disseminated neoplasia in *M. chilensis* (Campalans et al. 1998) in Chiloe Island, Chile (10). Finally, a case of disseminated neoplasia in *M. trossulus* was reported in the West Pacific, Sea of Japan (11) at Nakhodka Bay close to Vladivostok, Russia (Usheva & Frolova 2000).

Disseminated neoplasia occurs in *Mytilus galloprovincialis* and *Mytilus edulis* at very low prevalences. Interestingly, Fuentes et al. (2002) suggested the existence of a depressed immune system in hybrid mussels (*Mytilus edulis/Mytilus galloprovincialis*), explaining their higher susceptibility to neoplasia compared with mussels from pure crosses. The case of disseminated neoplasia in mussels from the Black Sea presented in this work, in association with similar cases in different *Mytilus* species reviewed above, demonstrates a wide geographical distribution of disseminated neoplasia in mussels in the world's oceans and estuaries.

ACKNOWLEDGEMENTS. This work was supported in part by a EU Marie Curie Intra-European Fellowship to Corina Ciocan, contract no: MEIF-CT-2003-500587. We are indebted to Dr. James Moore from the University of California, Davis for his comments on the manuscript. Shannon Kelly is acknowledged for editing the manuscript.

REFERENCES

- Bower, S.M. 1989. The summer mortality syndrome and hemocytic neoplasia in blue mussels (*Mytilus edulis*) from British Columbia. Canadian Technical Report of Fisheries and Aquatic Sciences 1703, 1-65.
- Brousseau, D. J. 1987. Seasonal aspects of sarcomatous neoplasia in *Mya arenaria* (soft-shell clam) from Long Island Sound. Journal of Invertebrate Pathology 50, 269-276.
- Campalans, M., Gonzales, M. & Rojas, P. 1998. Neoplasia in *Mytilus chilensis* cultivated in Chiloe Island (Chile). Bulletin of European Association of Fish Pathologists 18, 93-95.
- Cosson-Mannevy, M.A., Wong, C.S. & Cretney, W.J. 1984. Putative neoplastic disorders in mussels (*Mytilus edulis*) from southern Vancouver Island waters, British Columbia. Journal of Invertebrate Pathology 44, 151-160.
- Elston, R.A., Kent, M.L. & Drum, A.S. 1988a. Progression, lethality and remission of hemic neoplasia in the bay mussel, *Mytilus edulis*. Diseases of Aquatic Organisms 4, 135-142.
- Elston, R.A., Kent, M.L. & Drum, A.S. 1988b. Transmission of hemic neoplasia in the baymussel, *Mytilus edulis*, using whole cells and cell homogenate. Developmental & Comparative Immunology 12, 719-727.

Elston, R.A., Drum, A.S. & Allen, S.K. Jr. 1990. Progressive development of circulating polyploid cells in *Mytilus* with hemic neoplasia. Diseases of Aquatic Organisms 8, 51-59.

Elston, R.A., Moore, J.D. & Brooks, K. 1992. Disseminated neoplasia of bivalve mollusks. Reviews in Aquatic Sciences 6, 405-466.

Farley, C.A. 1969. Sarcomatid proliferative disease in a wild population of blue mussels (*Mytilus edulis*). Journal of the National Cancer Institute 43, 509-516.

Farley, C.A. 1976. Ultrastructural observations on epizootic neoplasia and lytic infection in bivalve mollusks. Progress in Experimental Tumor Research 20, 283-294.

Farley, C.A., Otto, S.V. & Reinisch, C.L. 1986. New occurrence of epizootic sarcoma in Chesapeake Bay soft shell clams, *Mya arenaria*. Fishery Bulletin 84, 851-857.

Farley, C.A., Plutschak, D.L. & Scott, R.F. 1991. Epizootiology and distribution of transmissible sarcoma in Maryland softshell clams, *Mya arenaria*, 1984-1988. Environmental Health Perspectives 90, 35-41.

Figueras, A.J., Jardon, C.F. & Caldas, J.R. 1991a. Diseases and parasites of rafted mussels (*Mytilus galloprovincialis* Lmk): preliminary results. Aquaculture 99: 17-33.

Figueras, A.J., Jardon, C.F. & Caldas, J.R. 1991b. Diseases and parasites of mussels (*Mytilus edulis* Linnaeus, 1758) from two sites on the east coast of the United States. *Journal of Shellfish Research* 10, 84-94.

Fuentes, J., López, J.L., Mosquera, E., Vázquez, J., Villalba, A. & Alvarez, G. 2002. Growth, mortality, pathological conditions and protein expression of *Mytilus edulis* and *M. galloprovincialis* crosses cultured in the Rias of Galicia (NW Spain). *Diseases of Aquatic Organisms* 31, 127-139.

Gosling, E. 1992. Genetics of *Mytilus*. In: Gosling, E. (ed.), *The Mussel Mytilus: Ecology, Physiology, Genetics and Culture*. Elsevier, Amsterdam, 309-382.

Green, M. & Alderman, D.J. 1983. Neoplasia in *Mytilus edulis* L. from United Kingdom waters. *Aquaculture* 30, 1-10.

Hillman, R.E. 1990. Incidence of neoplasia in west coast bivalves collected during phases 1,2 and 3 of the Mussel Watch Program, presented at the 1990 Mussel Watch Conference, Sequim, WA.

Hillman, R.E., Lordo, R.A., Menton, R.G., Peven, C.S., Uhler, A.D., Crecelius, E. & Steinhauer, W.G. 1992. Relationship of environmental contaminants to occurrence of neoplasia in mussels (*Mytilus edulis*) from east and west coast Mussel Watch sites. *Proceedings of the Marine Technology Society* 1, 230-239.

House, M.L., Kim, C.H. & Reno, P.W. 1998. Soft shell clams *Mya arenaria* with disseminated neoplasia demonstrate reverse transcriptase activity. *Diseases of Aquatic Organisms* 34, 187-192.

Kent, M.L., Elston, R.A., Wilkinson, M.T. & Drum, A.S. 1989. Impaired defense mechanisms in bay mussels, *Mytilus edulis*, with hemic neoplasia. *Journal of Invertebrate Pathology* 53, 378-386.

Kent, M.L., Elston, R.A., Wilkinson, M.T. & Drum, A.S. 1991. Failure of transmission of hemic neoplasia in bay mussels, *Mytilus trossulus*, to other bivalve species. *Journal of Invertebrate Pathology* 57, 435 – 436.

Lowe, D.M. & Moore, M.N. 1978. Cytology and quantitative cytochemistry of a proliferative atypical hemocytic condition in *Mytilus edulis* (Bivalvia, Mollusca). *Journal of the National Cancer Institute* 60, 1455-1459.

Medina, D.J., Paquette, G.E., Sadisar, E.C. & Chang, P.W. 1993. Isolation of infectious particles having reverse transcriptase activity and producing hematopoietic neoplasia in *Mya arenaria*. *Journal of Shellfish Research* 12, 112 –115.

Mix, M.C. 1983. Haemic neoplasms of bay mussels, *Mytilus edulis* L. from Oregon: occurrence, prevalence, seasonality and histopathological progression. *Journal of Fish*

Diseases 6, 239-248.

Moore, J.D., Elston, R.A., Drum, A.S. & Wilkinson, M.T. 1991. Alternate pathogenesis of systemic neoplasia in the bivalve mollusc *Mytilus*. *Journal of Invertebrate Pathology* 58, 231-243.

Oprandy, J..J., Chang, P.W., Provonost, A.D., Cooper, K.R., Brown, R.S. & Yates, V.J. 1981. Isolation of a viral agent causing hemopoietic neoplasia in the soft-shell clam, *Mya arenaria*. *Journal of Invertebrate Pathology* 38, 45-51.

Oprandy, J..J. & Chang, P.W. 1983. 5-Bromdeoxyuridine induction of hematopoietic neoplasia and retrovirus activation in the soft-shell clam, *Mya arenaria*. *Journal of Invertebrate Pathology* 42, 196-206.

Peters, E.C. 1988. Recent investigations on the disseminated sarcomas of marine bivalve mollusks. *American Fisheries Society Special Publication* 18, 74-92.

Peters, E.C., Yevich, P.P., Harshbarger, J.C. & Zaroogian, G.E. 1994. Comparative histopathology of gonadal neoplasms in marine bivalve mollusks. *Diseases of Aquatic Organisms* 20, 59-76.

Rasmussen, L.P.D. 1986. Occurrence, prevalence and seasonality of neoplasia in the marine mussel *Mytilus edulis* from three sites in Denmark. *Journal of Invertebrate*

Pathology 48, 117-123.

Reinisch, C.L., Charles, A.M. & Stone, A.M. 1984. Epizootic neoplasia in soft shell clams collected from New Bedford Harbor. Hazard Waste 1, 73-81.

Sunila, I. 1987. Histopathology of mussels (*Mytilus edulis* L.) from the Tvärminne area, Gulf of Finland (Baltic Sea). Annales Zoologici Fennici 24, 55-69.

Tiscar, P.G., Zizzo, N., Compagnucci, R. & Iaffaldano, D. 1990. Dati preliminary sulla patologia infettiva ed infestiva dei molluschi eduli lamellibranchi allevati o raccolti sui litorali Pugliesi. Atti della Societa Italiana delle Scienze Veterinarie XLIV, 709-712.

Twomey, E. & Mulcahy, M.F. 1984. Epizootiological aspects of a sarcoma in the cockle *Cerastoderma edule*. Diseases of Aquatic Organisms 5, 225-238.

Usheva, L.N. & Frolova, L.T. 2000. Neoplasia in the connective tissue of the mussel *Mytilus trossulus* from polluted areas of Nakhodka Bay, Sea of Japan. Russian Journal of Developmental Biology 31, 53-57.

Villalba, A., Mourelle, S.G., Carballal, M.J. & López, C. 1997. Symbionts and diseases of farmed mussels *Mytilus galloprovincialis* throughout the culture process in the Rias of Galicia (NW Spain). Diseases of Aquatic Organisms 31, 127-139.

Zizzo, N., Tiscar, P.G. & Troncone, A. 1991. Neoplasia in mitili (*Mytilus galloprovincialis*). Bollettino della Società Italiana di Patologia Ittica 7, 19-21.

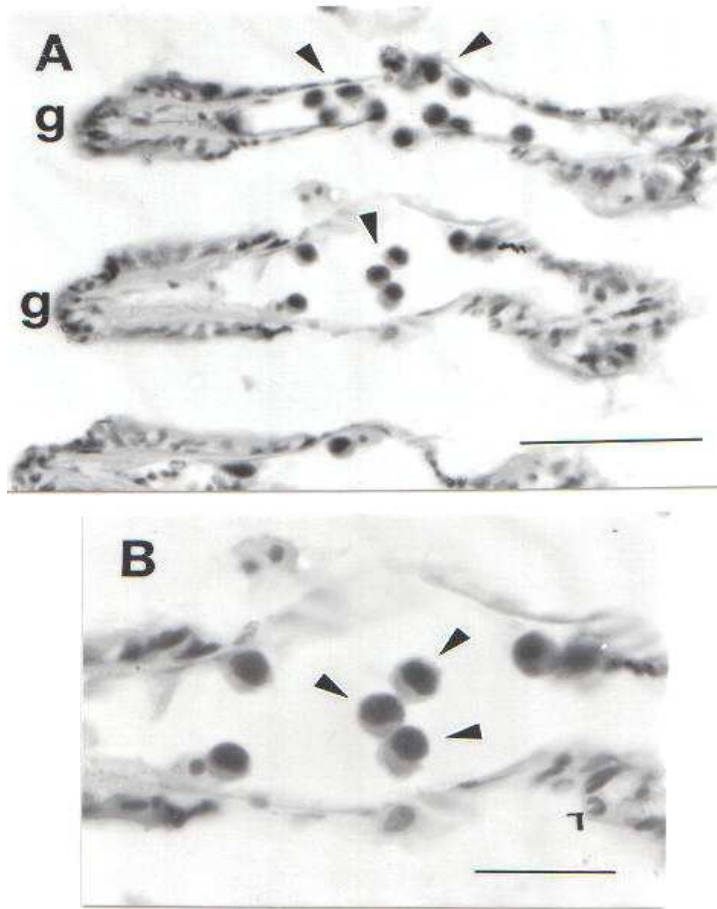


Fig. 1. A. Disseminated neoplasia in the mussel *Mytilus galloprovincialis* from Romania, Black Sea. Gill filaments with neoplastic cells. G=gill filament, arrows point to neoplastic cells. Paraffin section, Masson-Gomori Trichrome stain. Scale bar 50µm. B. Higher magnification of Fig. 1B. Arrows point to neoplastic cells. Scale bar 25µm.

Fig. 2. Geographical distribution of disseminated neoplasia in different species of blue mussels *Mytilus* sp.

