

# Sussex Research

## Three-dimensional digital template atlas of the Macaque brain

Colin Reveley, Audru<sup>nas</sup> Gruslys, Frank Q Ye, Daniel Glen, Jason Samaha, Brian E Russ, Ziad Saad, Anil Seth, David A Leopold, Kadharbatcha S Saleem

### Publication date

01-09-2017

### Licence

This work is made available under the **Copyright not evaluated** licence and should only be used in accordance with that licence. For more information on the specific terms, consult the repository record for this item.

### Document Version

Accepted version

### Citation for this work (American Psychological Association 7th edition)

Reveley, C., Gruslys, A., Ye, F. Q., Glen, D., Samaha, J., Russ, B. E., Saad, Z., Seth, A., Leopold, D. A., & Saleem, K. S. (2017). *Three-dimensional digital template atlas of the Macaque brain* (Version 1). University of Sussex. <https://hdl.handle.net/10779/uos.23433095.v1>

### Published in

Cerebral Cortex

### Link to external publisher version

<https://doi.org/10.1093/cercor/bhw248>

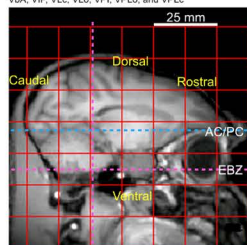
### Copyright and reuse:

This work was downloaded from Sussex Research Open (SRO). This document is made available in line with publisher policy and may differ from the published version. Please cite the published version where possible. Copyright and all moral rights to the version of the paper presented here belong to the individual author(s) and/or other copyright owners unless otherwise stated. For more information on this work, SRO or to report an issue, you can contact the repository administrators at [sro@sussex.ac.uk](mailto:sro@sussex.ac.uk). Discover more of the University's research at <https://sussex.figshare.com/>

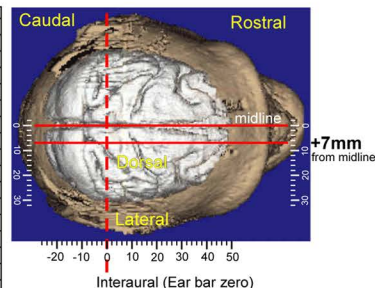
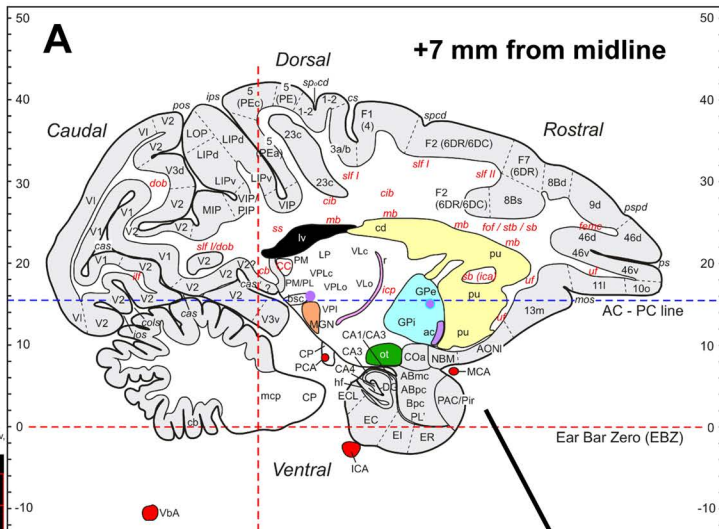
# Figure 1

## Abbreviations

EI entorhinal cortex, intermediate division  
 ER entorhinal cortex, rostral division  
 F1 agranular frontal area F1 (or 4)  
 F2 agranular frontal area F2 (or 6DR/6DC)  
 F7 agranular frontal area F7 (or 6DR)  
 femc fibers of the extreme capsule  
 for fronto-occipital fasciculus  
 GPu globus pallidus, external segment  
 GPI globus pallidus, internal segment  
 hf hippocampal fissure  
 ica internal capsule, anterior limb  
 ICA internal carotid artery  
 icp internal capsule, posterior limb  
 if inferior longitudinal fasciculus  
 ios inferior occipital sulcus  
 ips intraparietal sulcus  
 LIPd lateral intraparietal area, dorsal subdivision  
 LIPv lateral intraparietal area, ventral subdivision  
 LOP lateral occipital parietal area  
 LP lateral posterior nucleus  
 lv lateral ventricle  
 mb muratoff bundle  
 MCA middle cerebral artery  
 mcp middle cerebellar peduncle  
 MGN medial geniculate nucleus  
 MIP medial intraparietal area  
 mos medial orbital sulcus  
 NBM nucleus basalis of Meynert  
 ot optic tract  
 PAC periamygdaloid cortex  
 PCA posterior cerebral artery  
 PE superior parietal lobule area (or 5)  
 PEa superior parietal lobule area (or 5)  
 PEC posterior intraparietal area  
 PIP piriform cortex  
 Plr lateral pulvinar  
 PL paralamina nucleus in amygdala  
 See the index of abbreviations for PM, pos, pe, psp, pu, r, sb, slf I, sp, spcd, ss, slf, u, V1, V2, V3d, V3v, VbA, VIP, VLc, VLo, VPI, VPLo, and VPLc



Interaural  
 (Ear bar zero)



*Saleem and Logothetis (2012)*

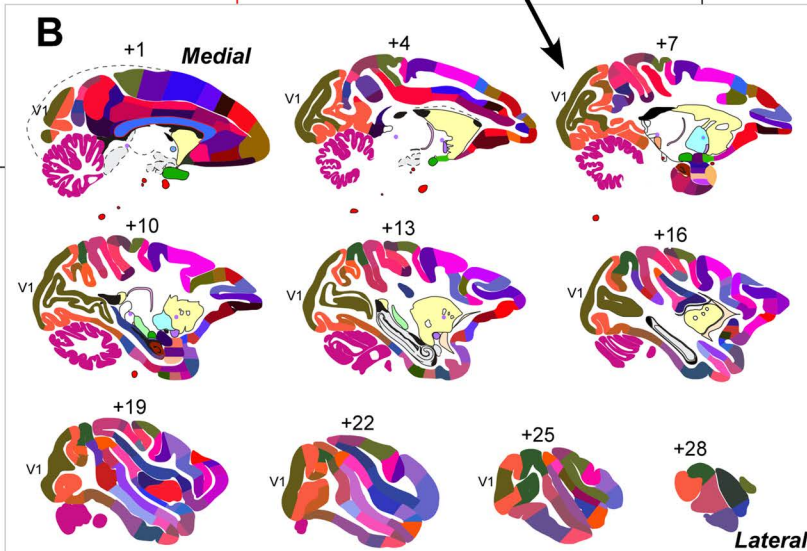


Figure 2

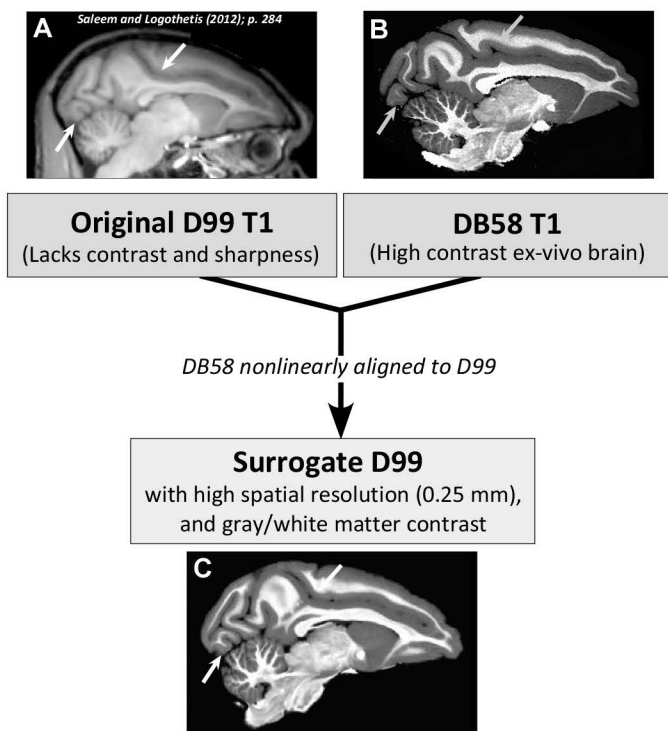


Fig. 3

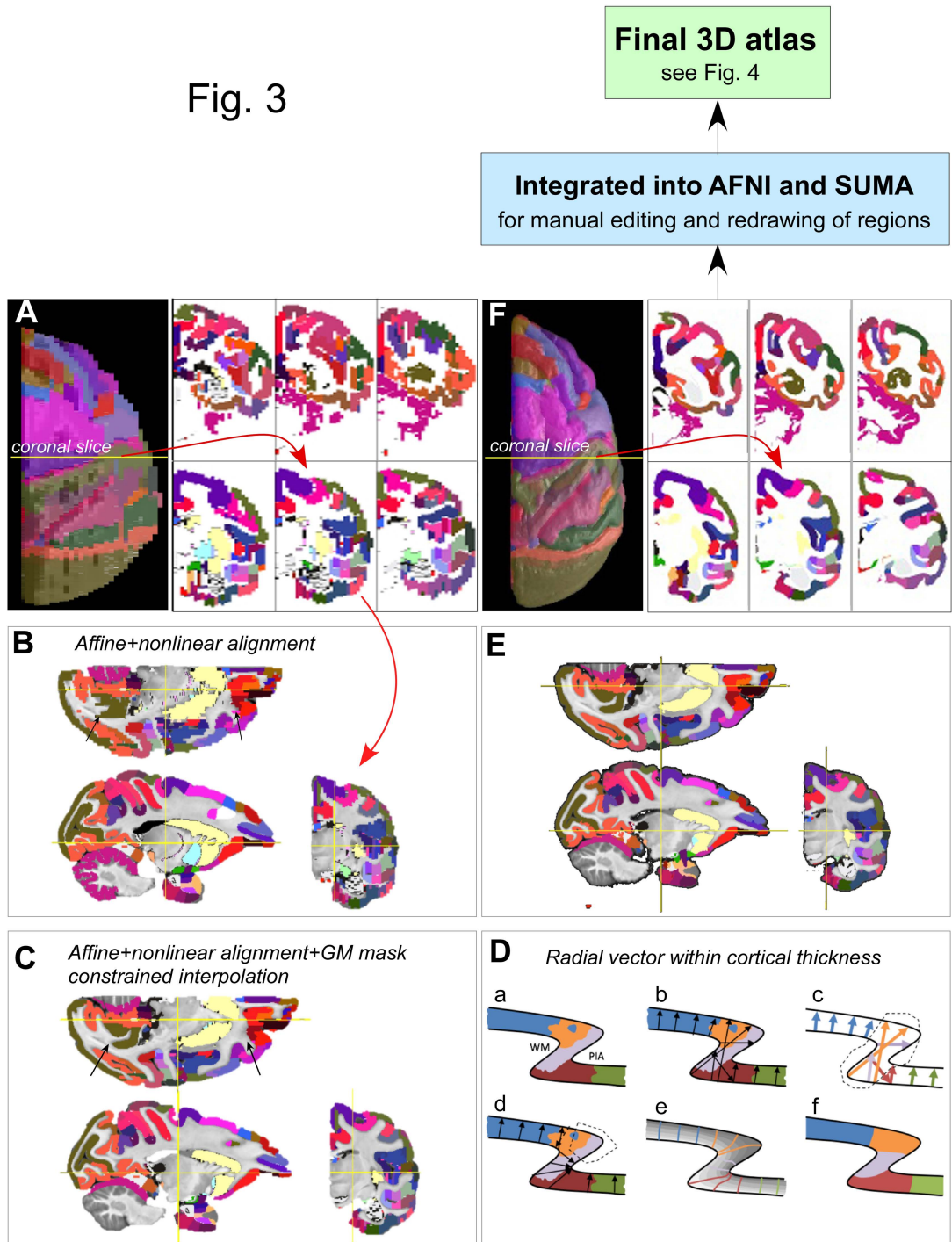
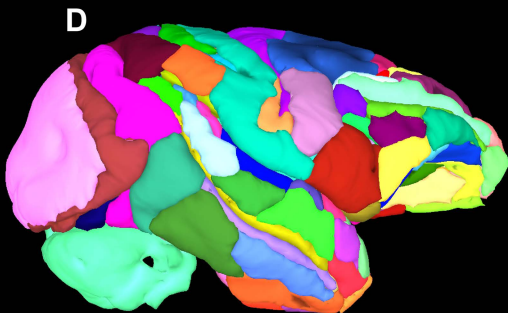
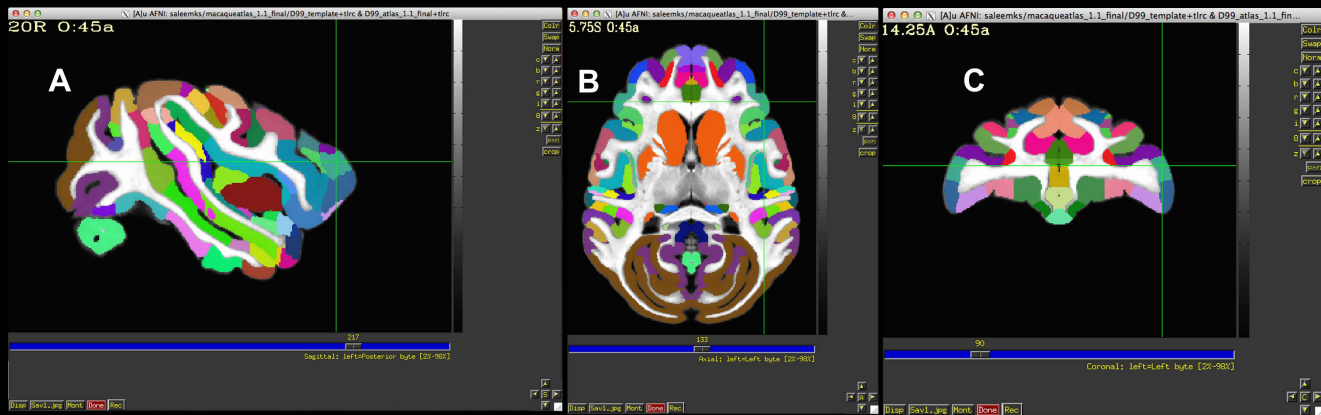
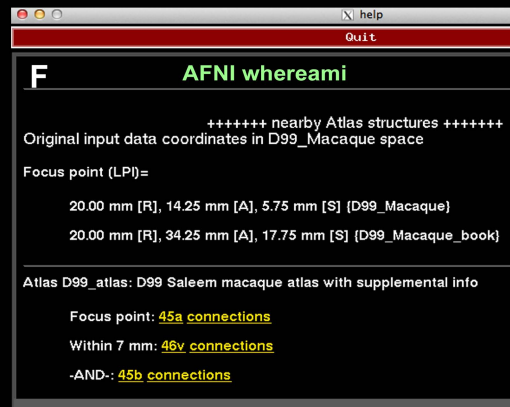
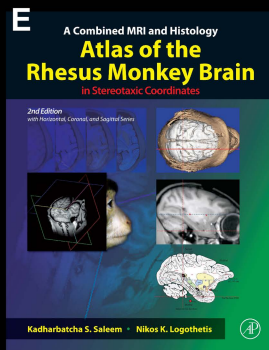


Fig. 4

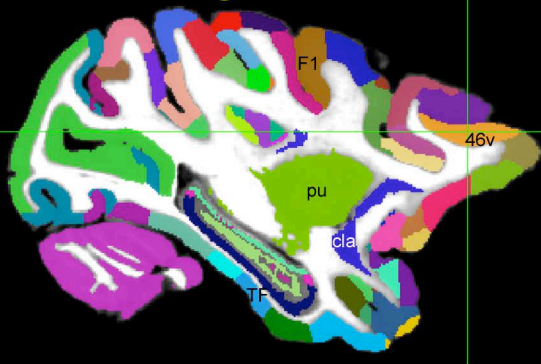


Saleem and Logothetis Atlas (2012)

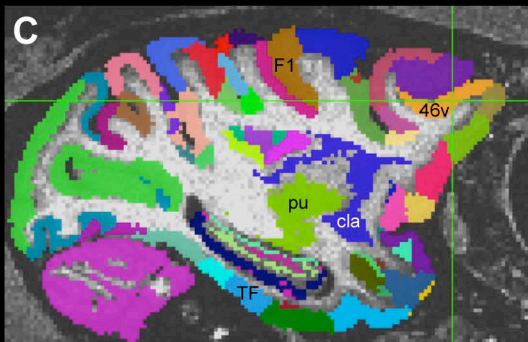




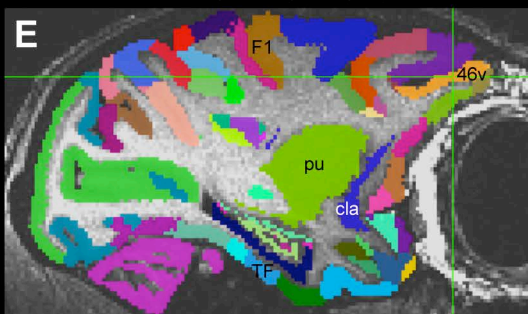
# A D99 Digital atlas



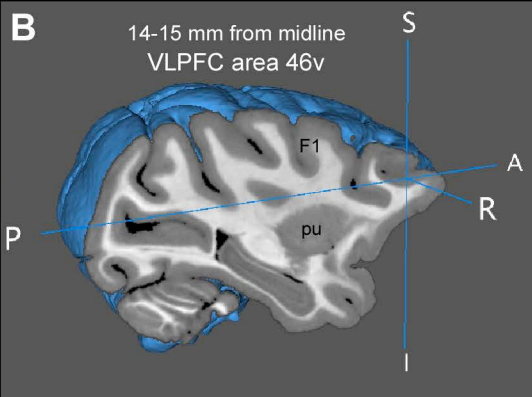
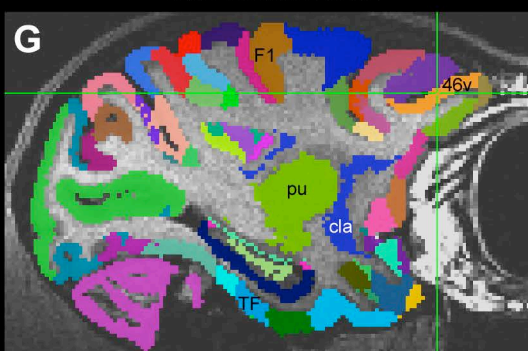
**Big male**  
14.25 mm from midline



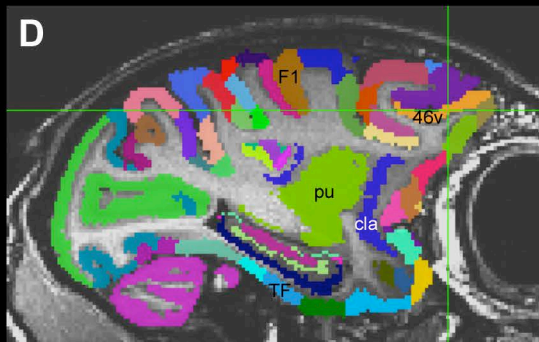
**Medium female**  
12.25 mm from midline



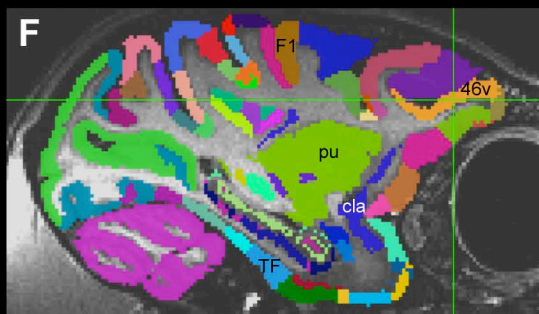
**Medium female**  
12.25 mm from midline



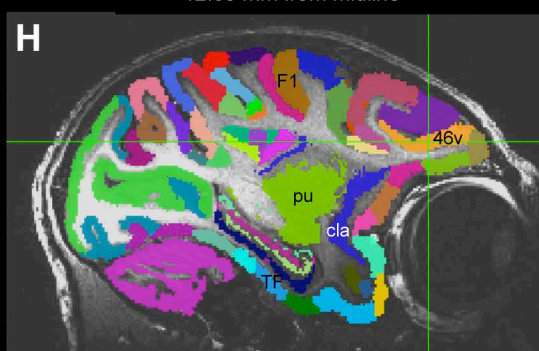
**Small female**  
12.75 mm from midline



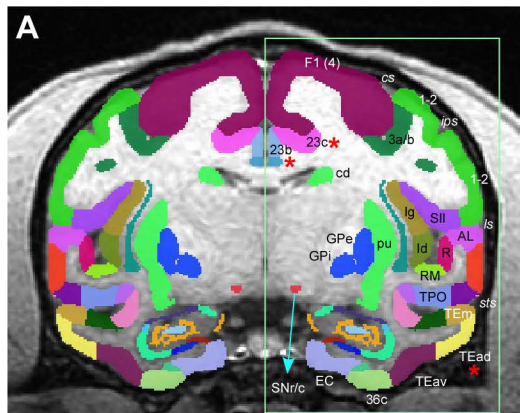
**small male**  
12.25 mm from midline



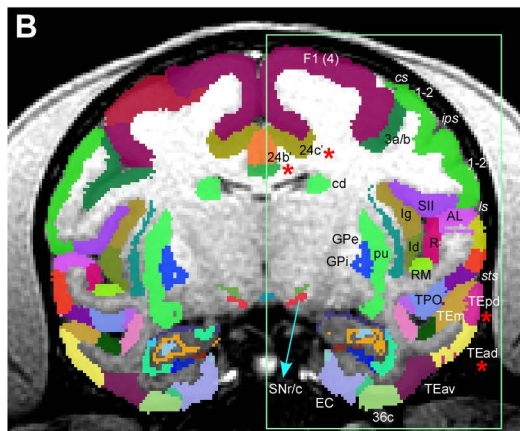
**very small female**  
12.05 mm from midline



## Subject MQ registered to Digital atlas

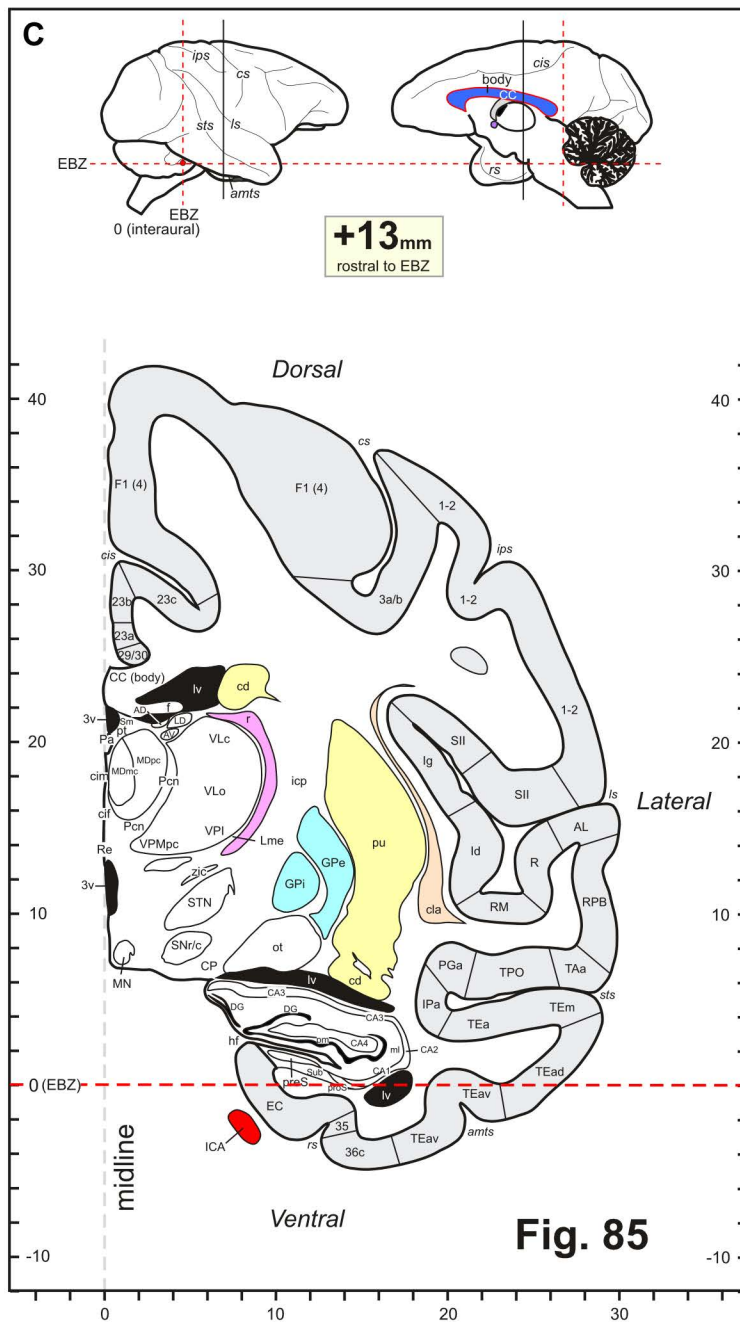


**Digital atlas registered to subject MQ**



Same section as in Fig. 7F

(slightly rotated to match with histology section shown in Fig. 7J)

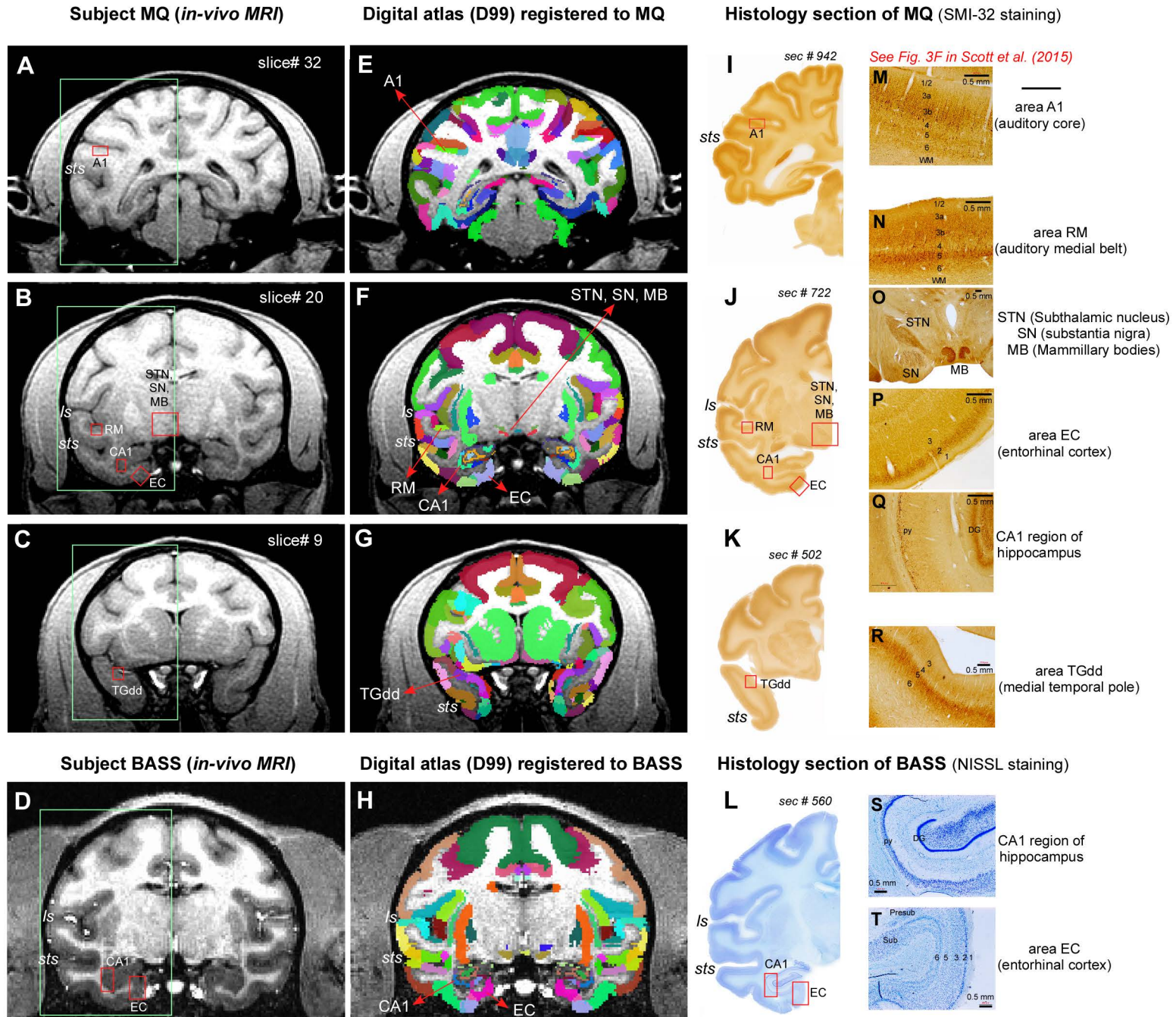


**Fig. 85**



Fig. 7

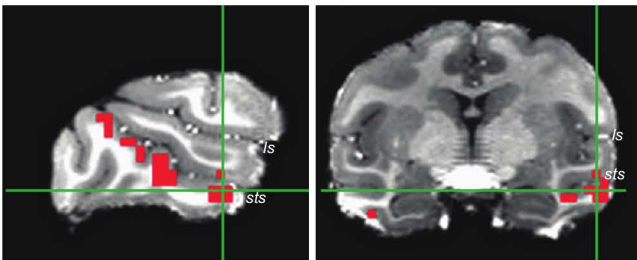
Registration of 3D atlas to test subjects with histological confirmation of architectonic areas



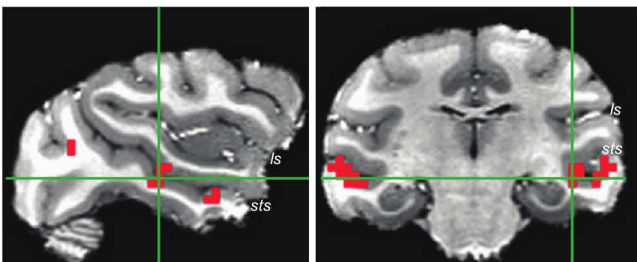


### A fMRI activation map on subject's anatomy

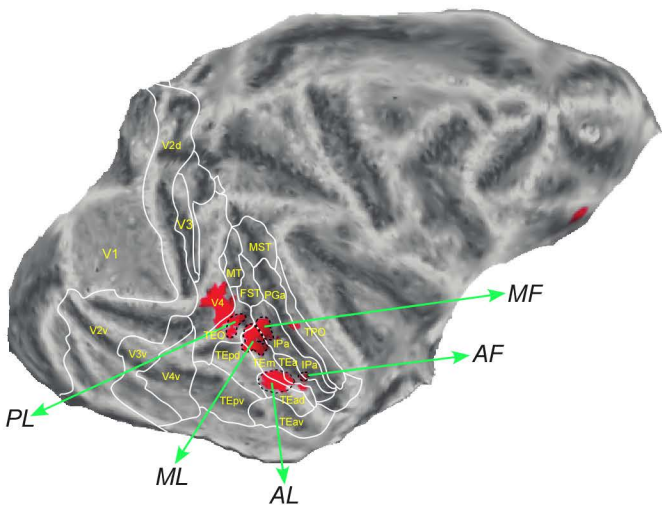
### Anterior Lateral (AL) Face Patch



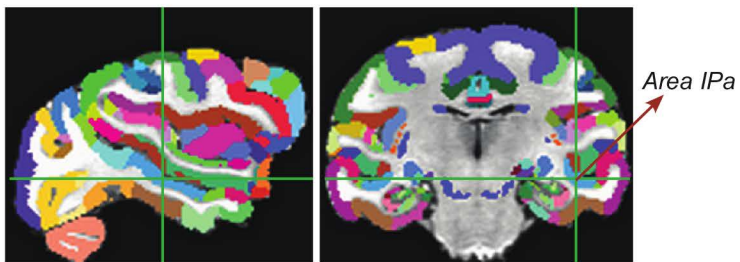
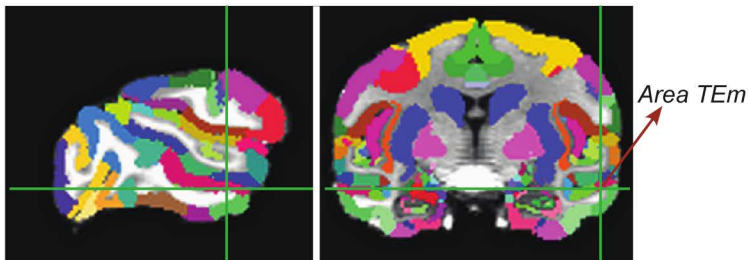
### Middle Fundus (MF) Face Patch



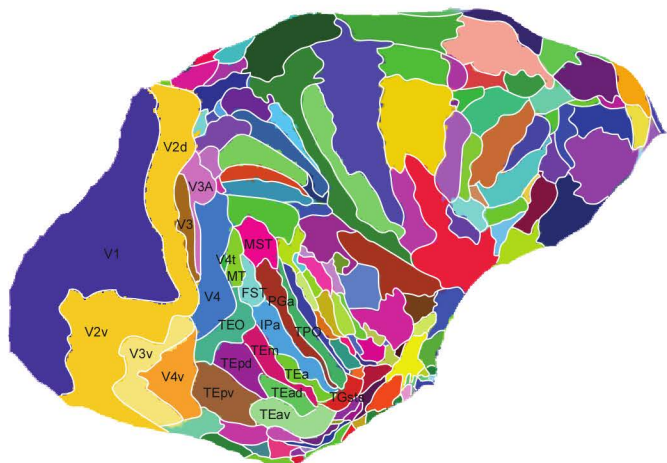
**C** fMRI activity projected on subject's flattened cortical surface



## B Digital atlas (D99) registered to subject's anatomy



**D** Digital atlas (D99) projected on subject's flattened cortical surface



Suppl. Figure 1

